

Osteotome Sinus Floor Elevation Without Grafting: A 10-Year Prospective Study

Rabah Nedir, DMD;¹ Nathalie Nurdin, PhD;² Lydia Vazquez, MD, DDS, PhD;³

Semaan Abi Najm, DMD, MS, ⁴ Mark Bischof, DMD⁵

¹ Clinical director, Swiss Dental Clinics Group, Ardentis Clinique Dentaire, Vevey, Switzerland.

² Senior scientist, Swiss Dental Clinics Group, Ardentis Clinique Dentaire, Vevey, Switzerland.

³ Assistant professor, Department of Orofacial Rehabilitation, Oral and Maxillofacial Radiology, University Clinics of Dental Medicine, University of Geneva, Geneva, Switzerland.

⁴ Clinical director, Swiss Dental Clinics Group, Ardentis Clinique Dentaire, Geneva, Switzerland; Senior lecturer, Department of Oral and Maxillofacial Surgery, Oral Surgery and Implantology Unit, Geneva University Hospitals, Geneva, Switzerland.

⁵ Clinical director, Swiss Dental Clinics Group, Ardentis Clinique Dentaire, Lausanne, Switzerland.

Corresponding author

Dr. Rabah Nedir, Ardentis Clinique Dentaire Vevey, Rue du Collège 3, 1800 Vevey, Switzerland; e-mail: rabah.nedir@ardentis.ch

Conflict of interest

The authors declare that they have no conflict of interest.

Author contributions

Rabah Nedir: Study concept and design, surgery, data interpretation, critical revision of the article, submission approval, article approval.

Nathalie Nurdin: Data collection and interpretation, statistical analysis, article writing and submission, article approval.

Lydia Vazquez: Data measurement, critical revision of the article, submission approval, article approval.

Seeman Abi Najm: Data interpretation, critical revision of the article, submission approval, article approval.

Mark Bischof: Patient enrolment, article revision, submission approval, article approval.

ABSTRACT

Background: Little is known about the long-term outcome of implants placed in the atrophic maxilla using osteotome sinus floor elevation (OSFE) without grafting.

Purpose: To evaluate the long-term efficiency of the procedure and stability of the peri-implant bone formed following implant placement without grafting into resorbed posterior maxilla.

Materials and Methods: Twenty-five implants (≤ 10 mm) were placed in 17 patients using OSFE without grafting. The mean residual bone height was 5.4 ± 2.3 mm. Bone levels were evaluated at 1, 3, 5 and 10 years using periapical radiographs.

Results: Fifteen patients (23 implants) participated in the 10-year examination. All implants fulfilled the survival criteria. Following surgery, the implant sites gained endo-sinus bone (mean: 3.0 ± 1.4 mm). The mean crestal bone loss (CBL) was limited to 1.0 ± 0.9 mm. The difference in mean endo-sinus bone gain and CBL was statistically significant between 1 and 10 years, but not between 3 and 5, 3 and 10 and 5 and 10 years.

Conclusions: At 10 years, the implant survival rate was 100%. Endo-sinus bone was mainly gained during the first year. This study demonstrates the long-term predictability of OSFE without grafting and simultaneous implant placement.

KEY WORDS: atrophic posterior maxilla; bone grafting; no grafting; long-term study; sinus osteotome; sinus lift

INTRODUCTION

Implant rehabilitation of the edentulous posterior maxilla is a challenging procedure. After tooth loss, alveolar bone resorption and pneumatization of the maxillary sinus occur. Consequently, the residual bone height (RBH) available for implant anchorage is reduced; in the majority of edentulous maxillary molar sites, the RBH is < 7 mm.¹ In the atrophic posterior maxilla, sinus grafting is an efficient procedure for implant-supported restoration.² To increase bone height in this area, sinus elevation is often performed using lateral window access and bone graft insertion. A healing period of 4-12 months before implant placement allows *de novo* bone formation.² This step prolongs the treatment time and increases the risk of morbidity when autogenous bone is used. The lateral approach, or sinus-lift, with textured implant placement has a success rate of up to 98.3% after 3 years.³

Osteotome sinus floor elevation (OSFE)⁴ is a simple and reliable approach to rehabilitation of the edentulous atrophic posterior maxilla. In most patients, a single surgical procedure is required to locally augment the posterior maxilla via crestal access and simultaneously place the implant. OSFE is less invasive and faster than the sinus-lift technique. Use of this procedure and placement of short implants minimize the need for extensive elevation of the sinus membrane and large volumes of graft material.⁵ Although 10-mm implants are most frequently inserted, 8- and 6-mm implants can also be used.⁶ OSFE yields predictable results, with success rates of at least 95%.⁷⁻⁹

Grafting is not a pre-requisite for bone formation in the atrophic maxilla because of the potential for healing and bone formation beneath the sinus membrane.¹⁰⁻¹⁵ No significant differences in survival or success rates have been found whether grafting material is used or not.^{16,17} Overall implant survival rates can reach 95% using OSFE

without grafting and simultaneous implant insertion when assessed after 1,^{13,16,18,19} 3^{15,17,20} and 5²¹ years. Antonaya-Mira and colleagues²² compiled the outcomes of 1250 implants placed in 751 patients using osteotome technique: in this study, 16.9% of the implants were placed without grafting material.

There is a paucity of prospective studies reporting the long-term (> 5 years) outcomes of implants placed in the atrophic maxilla using the OSFE technique. Misch and colleagues²³ compiled data on 757 implants placed using a standardized surgical protocol in an adequate volume of native bone in the posterior maxilla; they calculated a 10-year implant survival rate of 99.3%. Recently, Schmitt and colleagues²⁴ reported the 10-year outcomes of implants placed in the very atrophic maxillae of 127 patients (mean RBH: 2.7 mm) using lateral sinus floor elevation and/or onlay bone grafting. The implant survival rate was 94.48%, with minimal change in vertical bone resorption. Ferrigno and colleagues⁶ reported a cumulative implant survival rate of 94.8%, after an observation period of up to 12 years, for 588 implants placed in 323 patients with OSFE and immediate implant placement.

In a follow-up of up to 5 years, the reliability of OSFE without grafting material was reported for 25 implants placed simultaneously to a sinus elevation procedure in 17 patients.^{13,20,21} The 5-year implant survival rate was 100%. The clinical performance of the implants over 10 years and peri-implant bone level measurements are documented for the same sample of patients in this study. The true 10-year implant survival rate is presented rather than the estimated cumulative rates often reported in the literature. This is the first prospective study to report the results of OSFE without grafting after 10 years. This 10-year follow-up report has two aims: firstly, to document the long-term outcomes of implants placed in the atrophic

posterior maxilla using OSFE without grafting, and secondly, to measure and analyse bone levels around these implants.

MATERIALS AND METHODS

Ethics committee

The 10-year follow-up protocol was approved by the ethics committee for human research of Vaud (Switzerland) under protocol reference number 393/12. Informed consent was obtained from all participants.

Inclusion and exclusion criteria

Patients were eligible for inclusion in this study if:

- they required implant treatment in the posterior maxilla (sites 14-17, 24-27);
- the OSFE procedure was performed without grafting material;
- 10-mm-long implants were used, shorter implants (6 and 8 mm) were inserted only in cases of sinus membrane perforation;
- the RBH between the crest and the sinus floor, measured on panoramic radiograph at each implant site, was ≤ 8 mm;
- over 1 mm of bone was present on the mesial and distal sides to ensure implant stability;
- the implant penetrated at least 2 mm into the sinus on the mesial or distal implant sides; and
- they did not wear a removable partial denture during the healing period.

Patient exclusion criteria were:

- medical history of acute or chronic sinusitis;
- active periodontal disease, diabetes and metabolic bone disease; and

- no primary implant stability;

Between April and December 2003, 17 patients (14 women and three men) were enrolled; their mean age was 54.2 ± 9.6 years (range: 38-69 years).

Surgical and prosthetic procedures

Details of procedures have been described in a previous study.¹³ OSFE without grafting was undertaken using standard endosseous dental implants (Standard/2.8 mm collar and Standard Plus/1.8 mm collar/SLA; Ø 4.1/Ø 4.8 × 10 mm; Straumann AG, Basel, Switzerland). A midcrestal incision was performed for flap elevation without a vertical or periosteal release incision. To gain access to the sinus floor, cortical bone perforation was performed using round burs of increasing diameter (Ø 1.4-3.1 mm). In Type II bone, drilling up to 1 mm away from the floor was continued with Ø 2.1, 2.8 and 3.5 mm drills until final preparation. In Types III and IV bone, osteotomes (Straumann AG) were used instead of drills. In all bone types, a Ø 2.8 mm sinus floor elevation osteotome (Straumann AG) was used. Light tapping with a mallet carefully imploded the sinus floor into the sinus cavity, elevating the Schneiderian membrane. The osteotomy was subsequently enlarged with a Ø 3.5 mm sinus floor elevation osteotome (Straumann AG) and the integrity of the membrane was controlled with an undersized Ø 2.1 mm depth gauge. Implants were placed without tapping. Twenty-one implants were 10-mm long; because membrane perforation occurred at four sites, three 8-mm-long implants and one 6-mm-long implant were placed.

At placement, all implants showed primary stability. Stability was achieved by the threads or by placing the implant deeper, resting the flared neck against the crestal bone. Implant was not submerged and the area was maintained prosthesis-

free. After a mean healing time of 3.1 ± 0.4 months, abutments were tightened with 35 Ncm torque. Sixteen molar and nine premolar sites were rehabilitated with implants supporting four single crowns and 14 fixed partial dentures (FPD) of two to three units. Details related to prostheses are given in Table 1.

Clinical and radiographic follow-up

The study hypothesis was that peri-implant bone formation would occur in the absence of grafting and that bone volume would be stable over at least 10 years.

The implant survival criteria proposed by Buser and colleagues²⁵ were used:

- the absence of clinically detectable implant mobility;
- the absence of pain or any subjective sensation;
- the absence of recurrent peri-implant infection; and
- the absence of continuous radiolucency around the implant.

Periapical radiographs were taken using the long-cone technique by the same investigator immediately after surgery and at 1, 3, 5 and 10 years; the implant placement radiograph served as the baseline. Radiographic measurements were done by the same investigator, who was not involved in patient selection and surgery. The following parameters were recorded at the mesial and distal sides for each implant, and then averaged:

- peri-implant bone levels;
- protrusion of the implant into the sinus; and
- peri-implant crestal bone levels.

The RBH was accurately measured on periapical radiographs after surgery, at the mesial and distal sides for each implant, and then averaged.

Figure 1 shows details of the landmarks used for radiographic assessments.

Statistical analysis

Descriptive statistics (mean and standard deviation) were used to present sinus bone levels, protrusion into the sinus and crestal bone levels measured on the mesial and distal implant sides. The non-parametric Wilcoxon matched pairs signed-rank test was used to compare the various radiographic parameters measured at follow-up examinations. The Student t test was used to test the mean RBH, protrusion height and endo-sinus bone gain between implants placed in non-perforated and perforated sites. The threshold value for statistical significance was set at $p < 0.05$.

RESULTS

The mean RBH was 5.4 ± 2.3 mm; on the mesial side it was 5.7 ± 2.6 mm and 5.1 ± 1.9 mm on the distal side. The difference in bone height between the mesial and the distal sides varied substantially, up to 6 mm (range 2-8 mm).¹³ Follow-up examinations took place at 1, 3, 5 and 10 years after surgery (Figure 2). All 17 patients (25 implants) completed the scheduled follow-up visits up to the 3-year examination.^{13,20} One patient (one implant) did not attend the 5-year examination,²¹ but presented at the 10-year visit. Two patients (two implants) died between the 5- and 10-year examinations. One of the deceased patients had Schneiderian membrane perforated during surgery. Fifteen patients (23 implants) attended the 10-year follow-up examination.

All studied implants were clinically stable at 1, 3, 5 and 10 years. No patient complained of pain and there were no signs of suppuration. At the 10-year visit, five patients reported benign and non-recurrent sinus-related pathologies during the preceding 5 years; none had undergone Schneiderian membrane perforation during

surgery. None of the six implants placed in an RBH of < 4 mm failed. One patient (two implants) was successfully treated for peri-implantitis in Year 7. At the 10-year examination, his implants were functional, with a probing depth of < 2 mm and no further bone loss. The overall implant survival rate was 100%. At 10 years, all prostheses but one were free of complications. The single complication was a minor fracture of the porcelain veneer. This occurred on the mesio-buccal side of a fixed partial denture of three units.

Figure 2 shows the radiographic follow-up of a patient from implant placement to the 10-year examination. It illustrates the radiographic evolution of sinus demarcation after OSFE without grafting material. Figure 3 reports the endo-sinus bone gain (ESBG) measured for all implants at each follow-up visit. X-ray examination showed that all implants gained endo-sinus bone after implant placement. The ESBG tended to increase for 3 years for most implants and the increase was more pronounced during the first year. During the last 5 years, 10 sites gained small amounts of endo-sinus bone (+ 0.4 mm). Table 2 presents the mean values and standard deviation of ESBG, crestal bone loss (CBL) and protrusion length measured after surgery and at 1, 3, 5 and 10 years and the significance of these measurements at these different milestones. Starting from 2.5 ± 1.2 mm in the first year, the mean ESBG was 3.1 ± 1.5 mm at 3 years, 3.2 ± 1.3 mm at 5 years and 3.0 ± 1.4 mm at 10 years. The difference in mean ESBG between 1 and 3, 1 and 5, and 1 and 10 years was statistically significant, but not that between 3 and 5, 3 and 10, and 5 and 10 years. The implant sites that experienced membrane perforation showed a mean ESBG of 3.2 ± 0.8 mm after 10 years, consistent with values obtained for implants placed without perforation (3.0 ± 1.5 mm).

The mean CBL was 1.2 ± 0.7 mm at 1 year and 0.9 ± 0.8 mm at 3 years. The 5-year examination showed that this parameter stabilized to 0.8 ± 0.8 mm. It increased slightly for 11 implants ($+ 0.6$ mm) between 5 and 10 years and reached 1.0 ± 0.9 mm at 10 years (range: 0-2.9 mm). Four implant sides exhibited a CBL of > 2 mm. The difference in mean CBL between 1 and 3, 1 and 5, and 1 and 10 years was statistically significant, but not that between 3 and 5, 3 and 10, and 5 and 10 years.

The mean implant protrusion length was 1.9 ± 1.2 mm at the 10-year examination. The apex of three implants became completely embedded in bone on at least one side and ceased to protrude into the sinus. The mean bone height around the implants was 7.5 ± 1.6 mm (range: 3.2-10 mm) after 10 years.

Membrane perforation occurred at four sites during surgery. Therefore, three 8-mm-long implants and one 6-mm-long implant were placed. The mean RBH at these four sites were 3.0 ± 1.3 mm while it was 5.8 ± 2.1 mm at the non-perforated sites ($p=0.006$). The differences in mean mean protrusion height and endo-sinus bone gain around implants placed in non-perforated and perforated sites were not statistically significant ($p > 0.05$; Table 3).

DISCUSSION

This clinical study presents the 10-year follow-up of a crestal approach for sinus augmentation without grafting material. Implants were placed in a mean RBH of 5.4 ± 2.3 mm simultaneously to OSFE surgery. They were prosthetically rehabilitated after a mean healing time of 3.1 ± 0.4 months. The results showed a 100% implant survival rate for up to 10 years. During this follow-up period, one case of peri-implantitis was successfully treated and only one minor prosthetic complication occurred on a fixed partial prosthesis. The literature indicates that, following use of

this technique, the prognosis may be more favourable when the RBH is at least 5 mm. For implants placed without grafting material, implant survival was 94.2% and 97.2% with residual ridge heights of < 5 mm (n = 241) and \geq 5 mm (n = 1151), respectively.²⁶ When the RBH is less than 4 mm, the survival rate is adversely influenced²⁷ and may decrease to 85.7% with grafting material.²⁸

Perforation of the sinus mucosa during implant placement to optimize implant anchorage does not lead to consequential sinus pathologies, such as sinusitis.^{29,30} In this study, none of the patients who complained of sinus-related pathologies during the 10-year follow-up period had been affected by Schneiderian membrane perforation during surgery. Use of the procedure without grafting material avoided all complications resulting from the presence of graft particles in the sinus cavity.³¹ Perforation of Schneiderian membrane occurred in the sites with lower RBH. It may not affect the long-term survival rate of implants placed using OSFE without grafting material. When membrane perforation was diagnosed, shorter implants (\leq 8 mm in length) were inserted to avoid excessive protrusion of the implant into the sinus cavity. The shorter implants exhibited the same favourable prognosis as the 10-mm-long implants over 10 years. The protrusion height and the endo-sinus bone gain measured around short implants placed in perforated sites are equivalent to these measured around 10-mm implants placed in non-perforated sites.

This study addressed the capacity of bone to form beneath the Schneiderian membrane after its elevation without grafting. Despite the lack of grafting, endo-sinus bone was gained around all implants. Elevation of the Schneiderian membrane into the sinus creates a space in which *de novo* bone is formed. Endo-sinus bone was mainly gained during the first 3 years and seemed to stabilize over time. The mean increase in bone height around the implants was 3.0 ± 1.4 mm at 10 years. This is

consistent with data reported in a review of the literature. Antonaya-Mira and colleagues²² reviewed 10 articles and reported on 1215 implants placed using OSFE with and without grafting material. Overall bone gain ranged from 2.28-5.55 mm after 0.5-12 years. Sul and colleagues³² investigated the outcome of implants protruding 4 mm into the sinuses of dogs without grafting material. The authors reported partial coverage of bone, with ESBG ranging from 2.5-3.6 mm (mean: 3.3 mm).

It is established that bone must be present both around the implant (at least 10 mm in length) and above its apex to guarantee long-term success.² Following a sinus elevation procedure, it is believed that the implant apex should be covered by a bony graft. In this study, however, the implant apexes were not embedded in bone. The mean protrusion length was 1.9 ± 1.2 mm and the total bone anchorage reached a mean value of 7.5 mm over 10 years.

It has been shown that ESBG surrounding implants placed using OSFE with grafting was significantly higher than that surrounding implants placed using OSFE without grafting after 6 months¹⁷ and 1 year.¹⁶ However, when grafting material was used, resorption of the augmented bony volume occurred over time. In regions augmented with autologous bone, significant shrinkage occurred during the first 12 months (19.27%) and the total vertical bone loss reached 28.14% after 10 years.²⁴ In a randomized clinical trial, the radiographic outcomes of implants placed using OSFE with and without grafting showed no significant differences after 3 years of observation because of notable shrinkage of the graft.¹⁷ ESBG reached 3 mm for both groups.

A recent animal study³³ reported the percentage of bone-implant contact and bone density for implants placed using OSFE with and without grafting. After 24 weeks, these values were higher for implants placed without grafting; the histological

results were identical for both groups of implants.³³ OSFE without grafting provides good stability in terms of endo-sinus bone levels.

Based on previous long-term studies,³⁴⁻³⁶ a mean CBL of 0.9-1.6 mm can occur during the first year of function and of 0.2 mm annually thereafter. In this study, most CBL measurements were < 2 mm at 10 years and the mean value was 1.0 mm. The CBL was limited and no significant difference was found between the 3-, 5- and 10-year measurements. This suggests that a steady rate of CBL is achieved during the first 3 years, following adaptation to the biomechanical environment.³⁷

CONCLUSION

The technique described in this study induced successful bone formation in the sinus floor by elevating the maxillary sinus membrane and simultaneously inserting dental implants without the use of grafting materials. This study demonstrates the long-term reliability of OSFE with simultaneous implant placement over 10 years. During this follow-up period, all implants fulfilled clinical and radiographic survival criteria. All implants, even those placed in sites with perforated Schneiderian membrane and without apex embedded in bone, showed no sinus pathology. Endo-sinus bone was mainly gained during the first year and reached 3 mm after 10 years; furthermore, the *de novo* bone that developed beneath the sinus membrane did not shrink over time. CBL was limited; bone levels around implants may reach a steady state at 3 years. In conclusion, OSFE without grafting should be considered for sinus augmentation of 3 mm during surgical planning. Implant rehabilitation of the edentulous atrophied posterior maxilla can be greatly simplified using this technique with implants \leq 10 mm in length. This procedure allows the treatment of compromised posterior maxillae with good long-term results.

REFERENCES

1. Pramstraller M, Farina R, Franceschetti G, Pramstraller C, Trombelli L. Ridge dimensions of the edentulous posterior maxilla: a retrospective analysis of a cohort of 127 patients using computerized tomography data. *Clin Oral Implants Res* 2011; 22:54–61.
2. Jensen OT, Shulman LB, Block MS, Iacone VJ. Report of the sinus consensus conference of 1996. *Int J Oral Maxillofac Implants* 1998; 13(Suppl): 11–45.
3. Pjetursson BE, Tan WC, Zwahlen M, Lang NP. A systematic review of the success of sinus floor elevation and survival of implants inserted in combination with sinus floor elevation. Part I: Lateral approach. *J Clin Periodontol* 2008; 35(Suppl 8):216–240.
4. Summers RB. The osteotome technique. Part 3. Less invasive methods in elevation of the sinus floor. *Compend Contin Educ Dent* 1994; 15:698–708.
5. Toffler M. The clinical and practical benefits of combining short Implants with minimally invasive osteotome sinus floor elevation in the treatment of the atrophic posterior maxilla. *Pract Proced Aesthet Dent* 2006; 18:185–192.
6. Ferrigno N, Laureti M, Fanali S. Dental implants placement in conjunction with osteotome sinus floor elevation: A 12-year life-table analysis from a prospective study on 588 ITI implants. *Clin Oral Implants Res* 2006; 17:194–205.
7. Emmerich D, Att W, Stappert C. Sinus floor elevation using osteotomes: a systematic review and meta-analysis. *J Periodontol* 2005; 76:1237–1251.
8. Esposito M, Grusovin MG, Rees J, et al. Interventions for replacing missing teeth: Augmentation procedures of the maxillary sinus. *Cochrane Database of Systematic Reviews* 2010; 17:CD008397.

9. Shalabi MM, Manders P, Mulder J, Jansen JA, Creugers NH. A meta-analysis of clinical studies to estimate the 4.5-year survival rate of implants placed with the osteotome technique. *Int J Oral Maxillofac Implants* 2007; 22:110–116.
10. Bruschi GB, Scipioni A, Celesini G, Bruschi E. Localized management of sinus floor with simultaneous implant placement. A clinical report. *Int J Oral Maxillofac Implants* 1998; 13:219–226.
11. Winter AA, Pollack AS, Odrich RB. Sinus/alveolar crest tenting (SACT): a new technique for implant placement in atrophic maxillary ridges without bone grafts or membranes. *Int J Periodontics Restorative Dent* 2003; 23:557–565.
12. Lundgren S, Andersson S, Gualini F, Sennerby L. Bone reformation with sinus membrane elevation: a new surgical technique for maxillary sinus floor augmentation. *Clin Implant Dent Relat Res* 2004; 6:165–173.
13. Nedir R, Bischof M, Vazquez L, Szmukler-Moncler S, Bernard JP. Osteotome sinus floor elevation without grafting material: a 1-year prospective pilot study with ITI implants. *Clin Oral Implants Res* 2006; 17:679–686.
14. Lai H, Zhang ZY, Wang F, Zhuang LF, Liu X. Resonance frequency analysis of stability on ITI implants with osteotome sinus floor elevation technique without grafting: a 5-month prospective study. *Clin Oral Implants Res* 2008; 19:469–475
15. Pjetursson BE, Ignjatovic D, Matuliene G, Brägger U, Schmidlin K, Lang NP. Transalveolar maxillary sinus floor elevation using osteotomes with or without grafting material. Part II: radiographic tissue remodeling. *Clin Oral Implants Res* 2009; 20:677–683.
16. Nedir R, Nurdin N, Khoury P, et al. Osteotome sinus floor elevation with and without grafting material in the severely atrophic maxilla. A 1-year prospective randomized controlled study. *Clin Oral Implants Res* 2013; 24:1257–1264.

17. Si MS, Zhuang LF, Gu YX, Mo JJ, Qiao SC, Lai HC. Osteotome sinus floor elevation with or without grafting: a 3-year randomized controlled clinical trial. *J Clin Periodontol* 2013; 40:396–403.
18. Nedir R, Nurdin N, Szmukler-Moncler S, Bischof M. Placement of tapered implants using an osteotome sinus floor elevation technique without bone grafting: 1-year results. *Int J Oral Maxillofac Implants* 2009; 24:727–733.
19. Taschieri S, Corbella S, Del Fabbro M. Mini-invasive osteotome sinus floor elevation in partially edentulous atrophic maxilla using reduced length dental implants: interim results of a prospective study. *Clin Implant Dent Relat Res* 2014; 16:185–193.
20. Nedir R, Bischof, M, Vazquez L, Nurdin N, Szmukler-Moncler S, Bernard JP. Osteotome sinus floor elevation without grafting material: 3-year results of a prospective pilot study. *Clin Oral Implants Res* 2009b; 20:701–707.
21. Nedir R, Nurdin N, Vazquez L, Szmukler-Moncler S, Bischof M, Bernard JP. Osteotome sinus floor elevation technique without grafting: a 5-year prospective study. *J Clin Periodontol* 2010; 37:1023–1028.
22. Antonaya-Mira R, Barona-Dorado C, Martínez-Rodríguez N, Cáceres-Madroño E, Martínez-González JM. Meta-analysis of the increase in height in maxillary sinus elevations with osteotome. *Med Oral Patol Oral Cir Bucal* 2012; 17:e146–e152.
23. Misch CE, Misch-Dietsh F, Silc J, Barboza E, Cianciola EJ, Kazor C. Posterior implant single-tooth replacement and status of adjacent teeth during a 10-year period: A retrospective report. *J Periodontol* 2008; 79:2378–2382.
24. Schmitt C, Karasholi T, Lutz R, Wiltfang J, Neukam FW, Schlegel KA. Long-term changes in graft height after maxillary sinus augmentation, onlay bone

- grafting, and combination of both techniques: a long-term retrospective cohort study. *Clin Oral Implants Res* 2014; 25:e38–e46.
25. Buser D, Mericske-Stern R, Bernard JP, et al. Long-term evaluation of non-submerged ITI implants. Part 1: 8-year life table analysis of a prospective multi-center study with 2359 implants. *Clin Oral Implants Res* 1997; 8:161–172.
 26. Del Fabbro M, Corbella S, Weinstein T, Ceresoli V, Taschieri S. Implant survival rates after osteotome-mediated maxillary sinus augmentation: a systematic review. *Clin Implant Dent Relat Res* 2012; 14(Suppl 1):e159–e168.
 27. Călin C, Petre A, Drafta S. Osteotome-mediated sinus floor elevation: a systematic review and meta-analysis. *Int J Oral Maxillofac Implants* 2014; 29:558–576.
 28. Rosen PS, Summers R, Mellado JR, et al. The bone-added osteotome sinus floor elevation technique: multicenter retrospective report of consecutively treated patients. *Int J Oral Maxillofac Implants* 1999; 14:853–858.
 29. Abi Najm S, Malis D, El Hage M, Rahban S, Carrel JP, Bernard JP. Potential adverse events of endosseous dental implants penetrating the maxillary sinus: long-term clinical evaluation. *Laryngoscope* 2013; 123:2958–2961.
 30. Jung JH, Choi BH, Jeong SM, Li J, Lee SH, Lee HJ. A retrospective study of the effects on sinus complications of exposing dental implants to the maxillary sinus cavity. *Oral Surg Oral Med Oral Pathol Oral Radiol Endod* 2007; 103:623–625.
 31. Levi PA, Marcuschamer E. Avoiding and managing complications for the lateral window technique. In: Kao DWK, ed. *Clinical Maxillary Sinus Elevation Surgery*. Ames: John Wiley & Sons, Inc. 2014: 93–94.
 32. Sul SH, Choi BH, Li J, Jeong SM, Xuan F. Effects of sinus membrane elevation on bone formation around implants placed in the maxillary sinus cavity: an

- experimental study. *Oral Surg Oral Med Oral Pathol Oral Radiol Endod* 2008; 105:684–687.
33. Si MS, Mo JJ, Zhuang LF, Gu YX, Qiao SC, Lai HC. Osteotome sinus floor elevation with and without grafting: an animal study in Labrador dogs. *Clin Oral Implants Res* 2013; doi: 10.1111/clr.12313.
 34. Adell R, Lekholm U, Rockler B, Brånemark PI. A 15-year study of osseointegrated implants in the treatment of the edentulous jaw. *Int J Oral Surg* 1981; 10:387–416.
 35. Albrektsson T, Zarb GA, Worthington P, Eriksson AR. The long-term efficacy of currently used dental implants: a review and proposed criteria of success. *Int J Oral Maxillofac Implants* 1986; 1:11–25.
 36. Lindquist LW, Rockler B, Carlsson GE. Bone resorption around fixtures in edentulous patients treated with mandibular fixed tissueintegrated prostheses. *J Prosthet Dent* 1988; 59:59–63.
 37. Mordenfeld A, Albrektsson T, Hallman M. A 10-year clinical and radiographic study of implants placed after maxillary sinus floor augmentation with an 80:20 mixture of deproteinized bovine bone and autogenous bone. *Clin Implant Dent Relat Res* 2014; 16:435–446

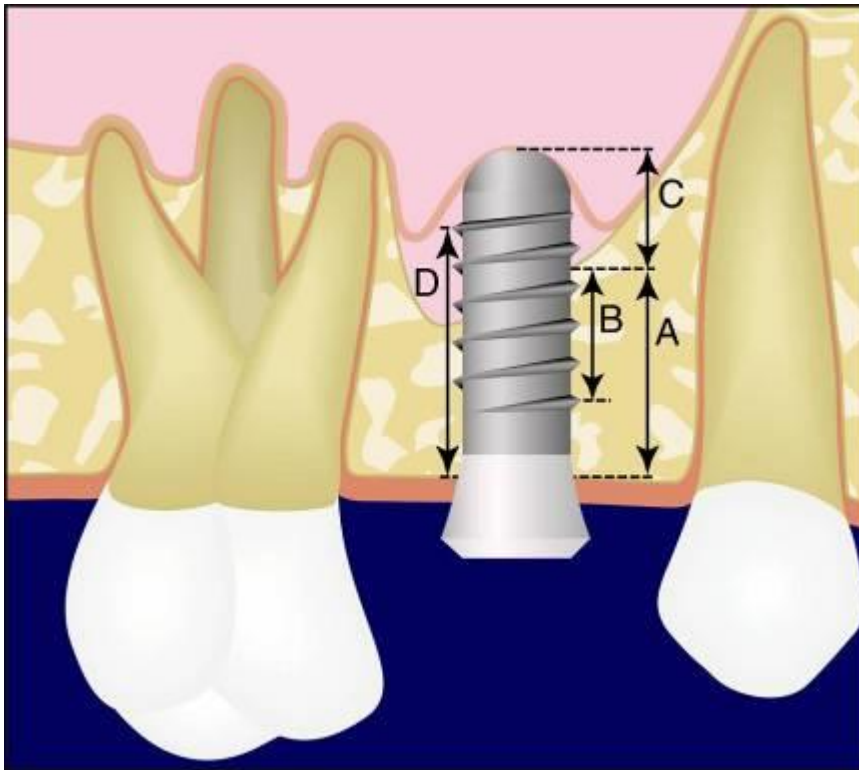


FIGURE 1 Schematic drawing of the parameters measured on radiographs.

(A) Bone height under the sinus. (B) Distance from the most coronal implant thread to the most apical visible implant–bone contact. Endo-sinus bone gain was calculated by subtracting the B-distances measured at 1-, 3-, 5- and 10-year examinations and immediately after implant placement. (C) Implant length protruding into the sinus. (D) Distance from the most coronal bone-implant contact to the most apical implant thread. Crestal bone loss was calculated by subtracting the D-distances measured at 1-, 3-, 5- and 10-year examinations and immediately after implant placement. Internal calibration was performed for each radiograph on three inter-thread distances (3.75 mm), given that the tips of two consecutive threads are separated by 1.25 mm.

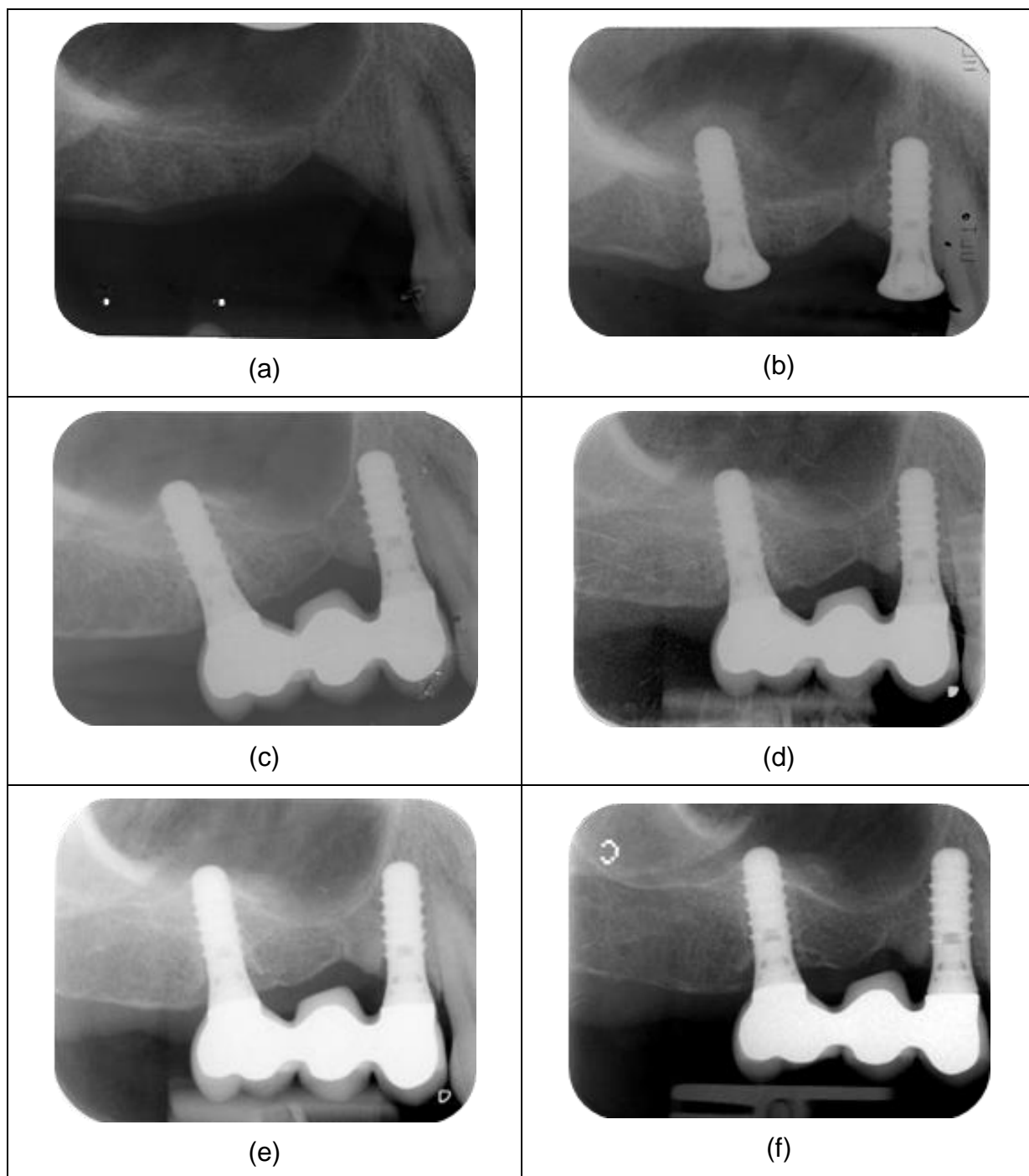


FIGURE 2 Radiographic evolution of sinus demarcation after the osteotome sinus floor elevation procedure without grafting material. Radiographs taken: (a) before implant placement; (b) immediately after implant placement; (c) at 1 year; (d) at 3 years; (e) at 5 years; and (f) at 10 years.

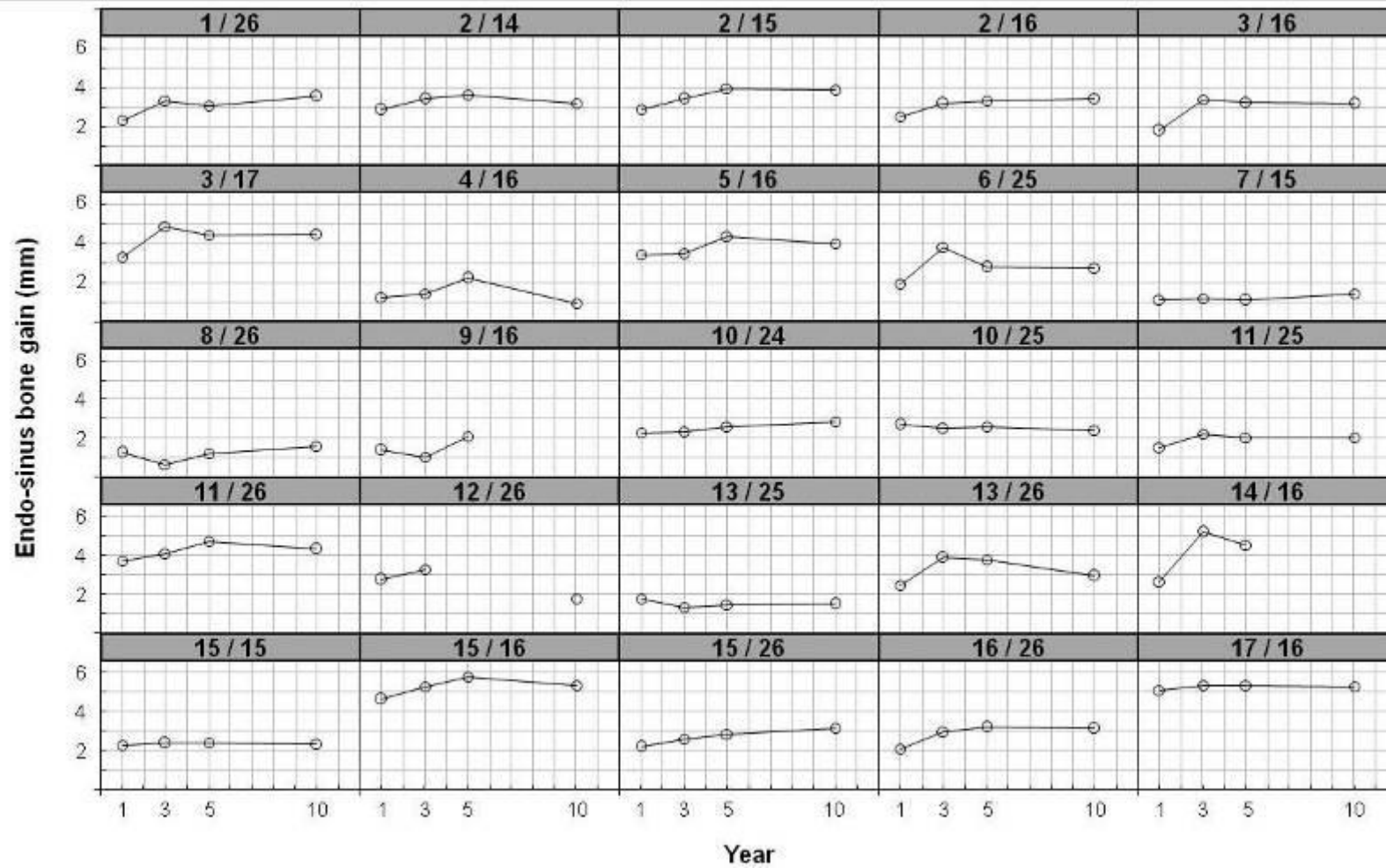


FIGURE 3 Endo-sinus bone gain (mean of distal and mesial sides, mm) around each implant (patient/site) measured at 1, 3, 5 and 10 years. The Schneiderian membrane of the patients 5 (site 16), 10 (site 25), 14 (site 16) and 16 (site 26) have been perforated during surgery.

Prosthesis type	No. prosthesis	No. studied implants
Single crown	4	4
FPD supported by 2 implants	10	12
2 units	1	2
2 units + 1 cantilever	4	5
2 units + 1 pontic	5	5
FPD supported by 3 implants	4	9
3 units	3	7
3 units + 1 pontic	1	2

TABLE 1 Distribution of prostheses.

	Endo-sinus bone gain	Crestal bone loss	Protrusion
Control			
Post surgery	-	-	4.9 ± 1.9 mm
Year 1	2.5 ± 1.2 mm	1.2 ± 0.7 mm	2.2 ± 1.0 mm
Year 3	3.1 ± 1.5 mm	0.9 ± 0.8 mm	1.8 ± 1.1 mm
Year 5	3.2 ± 1.3 mm	0.8 ± 0.8 mm	1.5 ± 0.9 mm
Year 10	3.0 ± 1.4 mm	1.0 ± 0.9 mm	1.9 ± 1.2 mm
p-value			
Years 1-3	< 0.001	0.002	0.010
Years 1-5	<0.001	0.001	<0.001
Years 1-10	<0.001	0.005	0.010
Years 3-5	0.204	0.054	0.001
Years 3-10	0.710	0.917	0.260
Years 5-10	0.423	0.123	0.053

TABLE 2 Endo-sinus bone gain, crestal bone loss and protrusion length (mean ± standard deviation) measured from radiographies taken after surgery and at 1, 3, 5 and 10 years. p-values express the significance of the difference in results between follow-up examinations.

	Non-perforated sites	Perforated sites	p
RBH	5.8 ± 2.1 mm (N = 21)	3.0 ± 1.3 mm (N = 4)	0.006
Protrusion Post surgery	4.8 ± 1.5 mm (N = 21)	5.2 ± 1.1 mm (N=4)	0.619
Protrusion Year 10	2.0 ± 1.1 mm (N = 20)	1.1 ± 1.8 mm (N = 3)	0.189
Endo-sinus bone gain Year 10	3.0 ± 1.2 mm (N = 20)	3.2 ± 1.8 mm (N = 3)	0.806

TABLE 3 Residual bone height, protrusion length, endo-sinus bone gain (mean ± standard deviation) measured from radiographies taken after surgery and at 10 years of sites with non-perforated and perforated Schneiderian membrane. p-values express the significance of the difference in mean values measured for sites with non-perforated and perforated Schneiderian membrane.